





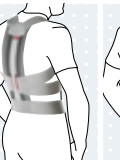









# Indication Matrix – Spine

	Necky Anatomic	Necky Color/Necky Color Forte	Philadelphia Cervical Brace	Smartspine Collar	Smartspine Universal Collar	Smartspine SI Support	Lumbo Carezza Basic	Lumbo Direxa Basic	Lumbo Sensa/Lumbo Sensa Women	Lumbo Therma	Lumbo Carezza	Lumbo Direxa/Women	Lumbo Direxa Stable	Smartspine LSO low	Lumbo TriStep
Article number	103 – 105	50C20/50C30	50C40	50C90	50C91	50R236	6001	6002	50R10/11	50R8	50R40	50R50/51	50R54	50R233	50R30
Indication	Low Stabilisation	Medium Stabilisation	Stabilisation/Immobilisation	Stabilisation/Immobilisation	Stabilisation/Immobilisation	Stabilisation	Low Stabilisation	Low Stabilisation	Low Stabilisation	Low Stabilisation	Low Stabilisation	Medium Stabilisation	Medium Stabilisation	Medium Stabilisation	High Stabilisation
<b>Cervical spine</b>															
Whiplash trauma	•	•	•	•	•										
Postoperative immobilisation			•	•	•										
Stenosis of the cervical spine			•	•	•										
Fractures of the cervical spine			•	•	•										
Degenerative changes of the cervical spine	•	•													
<b>Thoracic spine</b>															
Scheuermann's disease															
Stable vertebral compression fractures (with no neurological deficits)															
Mechanical thoracic kyphosis (hunchback, no fused vertebrae)															
Degenerative changes of the thoracic spine															
Facet joint syndrome of the thoracic spine															
Osteochondrosis of the thoracic spine															
Osteoporosis															
Osteoporotic fractures of the thoracic spine															
<b>Lumbar spine</b>															
Low back pain							•	•	•	•	•	•	•	•	•
Muscular imbalances									•	•	•	•	•		
Degenerative changes of the lumbar spine							•	•	•	•	•	•	•		•
Facet joint syndrome									•	•	•	•	•	•	•
Intervertebral disc protrusion												•	•		•
Intervertebral disc prolapse												•	•		•
Spinal stenosis of the lumbar spine														•	•
Stable vertebral compression fractures (with no neurological deficits)															•
Spondylolysis															•
Spondylolisthesis														•	•
Discectomy												•	•		•
Symphysiolysis						•									
Irritation of the sacroiliac joint						•									
Instability of the sacroiliac joint						•									

# Indication Matrix – Spine

	Smartspine LSO standard	Dorso Direxa Basic	Lumbo Carezza High	Lumbo Direxa High	Smartspine LSO high	Dorso Carezza Basic Posture	Dorso Carezza Posture	Dorso Direxa Posture	Dorso Osteo Care	Smartspine Extension Brace	Dorso Arexa	Hyperextension Brace	Hyperextension Brace	Smartspine TLSO
<b>Article number</b>	50R235	6005	50R42	50R52	50R232	6000	50R49	50R59	50R20	50R231	28R140N	28R14	28R16	50R230
														
<b>Indication</b>	High Stabilisation	Low Stabilisation	Low Stabilisation	Medium Stabilisation	High Stabilisation	Slight Straightening	Slight Straightening	Medium Straightening	Strong Straightening	Straightening/Immobilisation	Immobilisation	Immobilisation	Immobilisation	High Stabilisation/Immobilisation
<b>Cervical spine</b>														
Whiplash trauma														
Postoperative immobilisation														
Stenosis of the cervical spine														
Fractures of the cervical spine														
Degenerative changes of the cervical spine														
<b>Thoracic spine</b>														
Scheuermann's disease								•	•	•	•			•
Stable vertebral compression fractures (with no neurological deficits)					•					•	•	•	•	•
Mechanical thoracic kyphosis (hunback, no fused vertebrae)										•				•
Degenerative changes of the thoracic spine		•	•	•		•	•	•	•	•				•
Facet joint syndrome of the thoracic spine			•	•				•		•				•
Osteochondrosis of the thoracic spine			•	•				•	•	•				•
Osteoporosis								•	•	•	•	•	•	
Osteoporotic fractures of the thoracic spine								•	•	•				
<b>Lumbar spine</b>														
Low back pain	•	•	•	•	•			•		•				
Muscular imbalances		•	•	•										
Degenerative changes of the lumbar spine		•	•	•	•			•						•
Facet joint syndrome	•		•	•	•			•						
Intervertebral disc protrusion				•	•									•
Intervertebral disc prolapse				•	•									
Spinal stenosis of the lumbar spine	•				•									
Stable vertebral compression fractures (with no neurological deficits)	•				•						•	•	•	•
Spondylolysis	•				•									
Spondylolisthesis	•				•									
Discectomy				•										
Symphysiolysis														
Irritation of the sacroiliac joint														
Instability of the sacroiliac joint														